

DIABETIC RETINOPATHY: PATIENT IDENTIFICATION AND MEASUREMENT OF THE DISEASE USING ANN

Shreekant J. Mane

Dept. of Electronics & Telecommunication Engineering
GES's R.H. Sapat College of Engineering, Management and
Research

Nasik-422005(M.S.) India
shreekant.mane@gmail.com

Prof. Mrs. A.V. Nikalje

Dept. of Electronics & Communication Engineering
Deogiri Institute of Engineering & Management Studies
Aurangabad-431001(M.S.) India
anita_walde@rediffmail.com

Abstract—Automatic detection of defects from Diabetic Patient Retinal Fundus Images can help to detect and observe Diabetic Retinopathy which is further leads to Diabetic Retinopathy complications. Mathematically strong system is required to calculate accurately DR features like localization micro aneurysms, hemorrhages, exudate and optic disk in a retinal image is presented in this project. Since these features has different intensity properties, geometric features and correlations are used to distinguish between them. We propose method for optic disk detection, where we first detect the major blood vessels and use the intersection of these to find the approximate location of the optic disk. This is further localized using color properties. We also show that many of the features such as the blood vessels, exudate and micro aneurysms and hemorrhages can be detected quite accurately using different morphological operations applied appropriately. Algorithms are used to effectively calculate and identify features from fundus image database with varied contrast, illumination and disease stages the success in finding the defects in DR affected patient iris fundus image. These compare very favorably with existing systems and promise real deployment of these systems.

Keywords—fundus image; ANN; Micro aneurysms; Exudates; Hemorrhages; Glaucoma;

I. INTRODUCTION

Diabetic retinopathy is impairments in the human iris. It is the one of the main reason of legal blindness in the working age group of developed and developing states. So this is widely observed eye disease in the world now a day where as doctors or Ophthalmologist compare to human population are very least in number so automatic detection system of required to diagnose diabetic retinopathy which help doctor in the treatment of the DR patient. Majority of this blindness can be prevented with proper eye examination and treatment by ophthalmologists who rely on the results of randomized clinical trials to guide their treatment of patients with diabetes. Early treatment requires sets of retinal images to be captured from different fields of an eye because ophthalmologists rely on multiple retinal images for disease diagnosis and evaluation and these images need to cover a required area of the retina. Each set of fundus photographs should be assessed for quality before the patient leaves the imaging center where image quality assessment required for clarity & focus, field

definition, and stereo effect of the fundus image is important to view the defects present Diabetic Retinopathy.



Fig. 1 Vision Affected by Diabetic Retinopathy. A. Normal Vision and B. Same Scene viewed by a Person with Diabetic Retinopathy

Diabetic retinopathy is commonly observed in patients who have diagnosed diabetic. DR has features of both micro vascular occlusion and leakage. The consequence of retinal capillary non perfusion is retinal hypoxia which in turn causes blindness. Furthermore many respectable researches in psychology have said that a person can always put a smile on his or her face but eyes usually reveal his or her true feelings. Characteristics of the retinal blood vessels play an important role in a variety of medical diagnoses. Measurements of the disease are needed to calculate vessel width, color, reflectivity, abnormal branching, and the occurrence of vessels of a certain width. Eyes are the only place where any person can directly see inside human eye with non invasive method. In real time without any invasive medical techniques a retinas blood vessels which are significant indicators to not only eye related diseases but also various other diseases. Advanced retinal imaging analysis approaches need to be developed and implemented according to the need of the patient's and medical practitioner. Diabetic retinopathy is a complication commonly observed in Diabetic Retinopathy patients. Vision of a person easily get affected due to defects arises in front of the macular region. Vision of healthy and diabetic retinopathy person is shown in Figure 1. The disease increases due to abnormalities blood vessels inside the retina.

The retina is an area lying at the back of the eyeball and other parts of human eye specify in given figure 1.2. In accordance with the earliest stage of the disease has the tiny

blood vessels or capillaries which become thinner, weaker and eventually they leak blood known as micro aneurysms. In figure 3 (b) a patient's sights at this stage is still good but an ophthalmologist can detect and notice the abnormalities in the retina. As the disease progresses some blood vessels are blocked. These trigger the retina to grow new blood vessels those are abnormal, fragile, and easily bleed as shown in figure 3 (c). In the later stage of the disease new blood vessels are grown continuously as well as scar tissue as shown in figure 3 (d). Ultimately retina will be detached from an eye.

B.

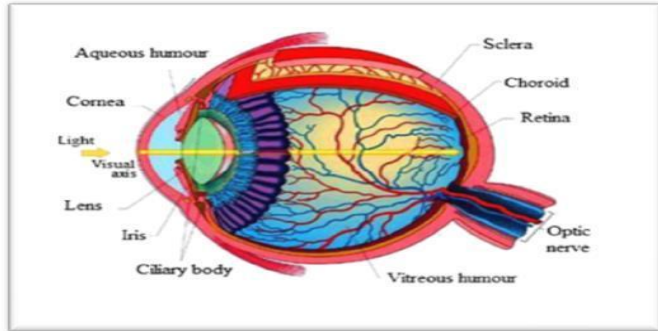


Fig. 2 Human Eye

National Eye Institute recommends everyone with diabetes to have comprehensive eye exam at least once a year because diabetic retinopathy has no early warning symptoms or signs. Failure to undergo universally recommended annual eye examinations is the primary cause of this continued loss of sight. If early diagnosis is done and proper treatment given to patient then the majority of the severe vision loss cases due to diabetic retinopathy can be prevented. Ophthalmologists primarily rely on the results of randomized clinical studies to guide their treatment of patients with diabetes. Retinal photography is important document in the diagnosis of various eye diseases in clinics. Color retinal images are widely used to mass screen systemic diseases such as diabetic retinopathy. Early detection and treatment of these diseases are crucial to avoid preventable vision loss. Early detection of the disease via regular screening is particularly important to prevent vision loss. In this process an automated DR diagnostic system can assist in a big way since a large population has to be screened and that too repeatedly. Color fundus images are used by ophthalmologists to study eye diseases like diabetic retinopathy. Early detection can enable timely treatment minimizing further deterioration. Clinical signs observable by digital film based fundus photography include microaneurysms, dot and blot hemorrhages, exudates and intra retinal micro vascular abnormalities. Following are the types of diabetic retinopathy, classified as per the severity of the disease. DR eye features calculation and identification is possible by using manual or automated method.

A. Mild non proliferative retinopathy: This is earliest stage of diabetic retinopathy where micro aneurysms occur in eye. They are small areas of balloon like swelling in the retina's tiny blood vessels.

Moderate non proliferative retinopathy: As the disease progresses some blood vessels that nourish the retina are blocked and swell.

C. Severe non proliferative retinopathy: Many more blood vessels are blocked, depriving several areas of the retina with their blood supply. These areas of the retina send signals to the body to grow new blood vessels for nourishment. Exudates and hemorrhages are observed due to leaking of blood vessels in eye initially.

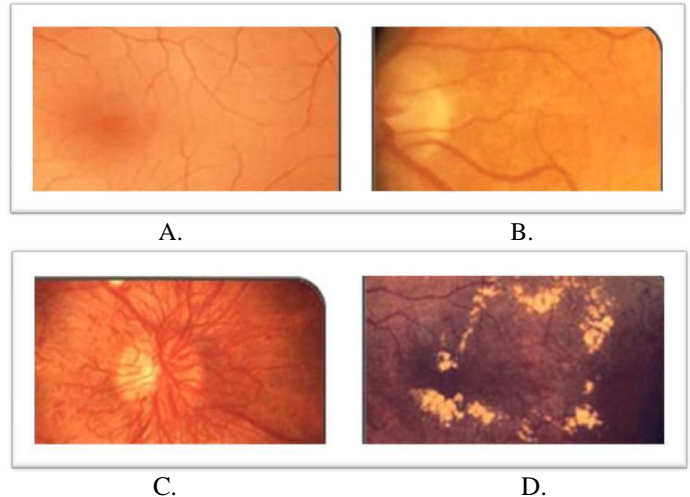


Fig.3 Different Stages of Diabetic Retinopathy A. an example of normal retinal image B. a retinal image with micro aneurysms C. proliferated diabetic retinopathy with fragile newly grown blood vessels and D. a retina image with some types of scar tissues.

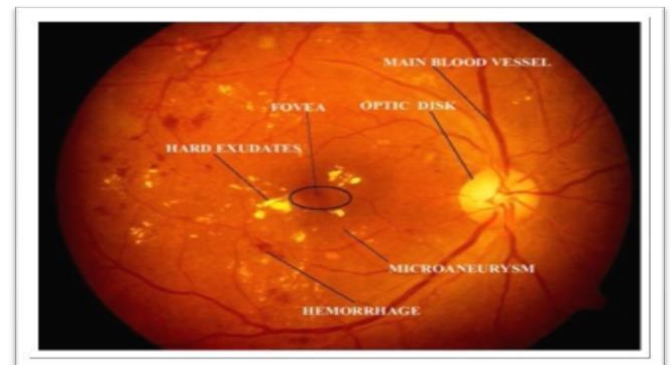


Fig. 4 Defects observed in DR Fundus Image

d) Proliferative retinopathy: This is advanced stage of retinopathy where signals are sent by the retina for nourishment trigger the growth of new blood vessels. This condition is called proliferative retinopathy. These new blood vessels are abnormal and fragile and grow along with the retina and the surface of the clear, vitreous gel that fills the inside of the eye.

Fundus image of DR patient given in figure 4 and labeled various feature components or defects which observed in diabetic retinopathy. Micro aneurysms are small blood clots caused by local distension of capillary walls and appear as

small red dots. This may also lead to big blood clots called hemorrhages. Hard exudates are yellow lipid deposits which appear as bright yellow lesions. The bright circular region from where the blood vessels emanate is called the optic disk. The fovea defines the center of the retina and is the region of highest visual acuity. The spatial distribution of exudates and micro aneurysms and hemorrhages especially in relation to the fovea can be used to determine the severity of diabetic retinopathy. The early treatment diabetic retinopathy study implemented standardized retinal imaging, classification and severity staging for diabetic retinopathy as well as proving the therapeutic of laser photocoagulation surgery in preventing vision loss. This multicenter randomized clinical trial designed to evaluate treatment of patients with non proliferative or early proliferative diabetic retinopathy. The study demonstrated a statistically significant reduction in severe visual loss for those eyes with early treatment. The fundus image required to diagnose DR uses topcons nw series camera which is shown in figure 5 used to capture image for further processing to analyze features to diagnose and treatment of the DR patient.

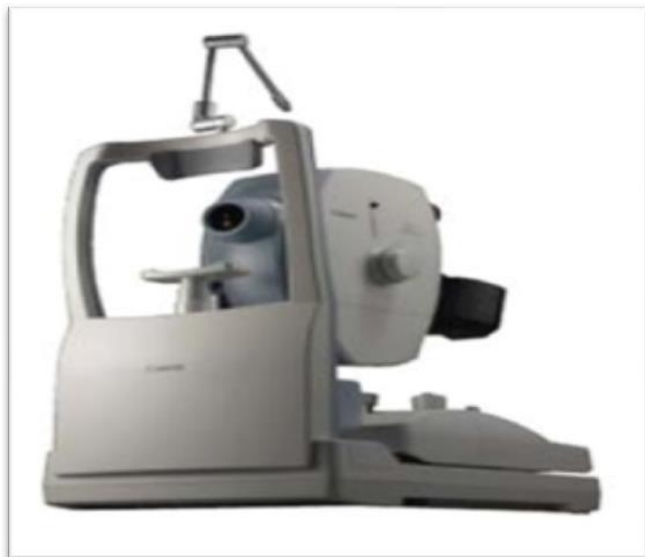

Fig. 5 Fundal Photography Equipment (Topcon NW Series)

II. NECESSITY

Diabetic retinopathy is one of the most serious complications of diabetes and a major cause of visual morbidity. It is a progressive disease classified according to the presence of various clinical abnormalities. DR is the most common cause of blindness in people aged 30 to 69 years. Manual methods of diagnosis may waste of time, cost and vision of patients. Some manual errors may occur while diagnosis process is going on. Retinal image classification has been done by various methods. Thomas Walter et. al used morphological reconstruction techniques for detection of the exudates known lipids of proteins which come out from damaged capillary vessels which is used to early stages of the Diabetic Retinopathy [1]. Joes Staal et. al performed vessel segmentation using kNN classifier and sequential forward feature selection on fundus Image which is required to extract

features of DR to evaluate stage of the given disease [2]. Alan D. Fleming et. al classify micro aneurysms using contrast normalization are compared where this enables to define early stages of the diabetic retinopathy [3]. Gary G. Yen et. al used hybrid intelligent system using ETDRS protocol developed to study grading of diabetic fundus image [4]. Arturo Aquino et. al used morphological and edge detection techniques followed by the circular hough transform to obtain a circular OD boundary approximation [5]. Keerthi Ram et. al define successive rejection based strategy using anisotropic filters, scale difference of Gaussian and inverted Gaussian methods to detect MA by avoiding clutter to obtain DR but severity of the disease cannot find using this method this limits the scope of the system [6]. Ramon Pires et. al provided theory of soft max bov, soft assignment coding and max pooling classification achieved area under the contours in DR patients which enables the detection of the severity [7].

Limitations of the existing systems or proposed works up till now evaluation of all defects arises due to DR compliances cannot extract using single method. Hence this developed system will overcome and able extract all features using single platform with the help of MATLAB.

III. OBJECTIVE

Various types of health hazards are observe now a days due to hectic life schedule, unhealthy diet plan. Consequences of DR are very complicated and severe so early detection of the disease is required. Following are the objective of this developed system.

1. To develop an efficient feature extraction algorithm that can effectively segment blood vessels and to select reliable point correspondences for latter processing.
2. To displaying the severity of the disease. This can be achieved by the area of the exudates and hemorrhages.
3. To propose a new constraint for optic disk detection where we first detect the major blood vessels first and use the intersection of these to find the approximate location of the optic disk

IV. THEME

In this project, fundus retinal image is used to diagnose diabetic retinopathy patient. Developed system used green plane outoff RGB component of image due more clarity. Green plane is selected because red planes have saturated features and blue plane has low intensity features while contours are easily viewed in green plane due to proper intensity features. Median filtering operation and histogram equalization operations is performing on a green plane to analyze various features in DR patient. Morphological operation like closing and opening (Dilation or Erosion) is required to identify feature accurately with the help of threshold value for Defects. Besides that Hough transform is used to isolate the features of the particular shape within an image. In the given system defects boundaries are created around the affected areas of the retina image and calculating the areas. According to the area of DR feature component and

with the help ANN by training and defining weights to the previous layer. Severity of the disease can be viewed with the help of GUI which display using feed forward back propagation network.

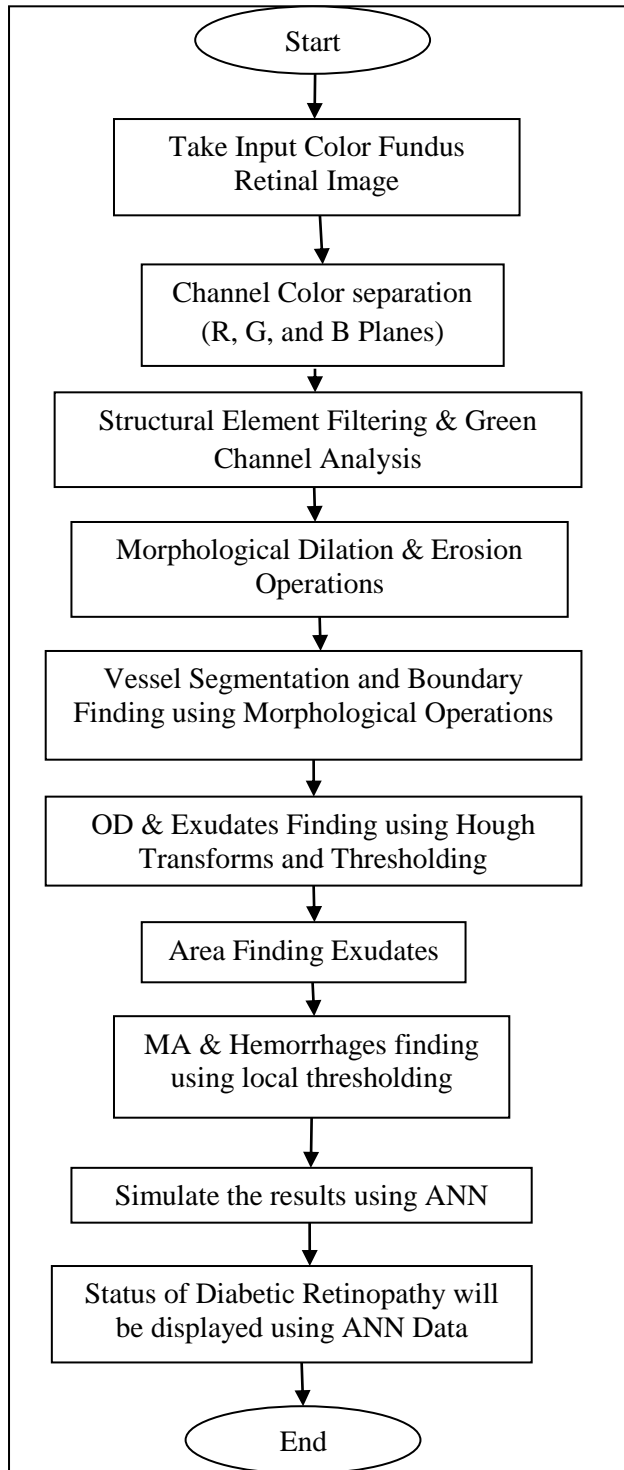


Fig. 6 Design Flow of the System

DR is a common retinal complication associated with diabetes and observes in higher age groups. It is a major cause of blindness in middle as well as older age groups. Therefore early detection through regular screening and timely

intervention will be highly beneficial in effectively controlling the progress of the disease. Since the ratio of people afflicted with the disease to the number of eye specialist who can screen these patients is very high. Need to have automated diagnostic system for diabetic retinopathy changes in the eye so that only diseased persons can be referred to the specialist for further intervention and treatment. Various aspects and stages of retinopathy are analyzed by examining the colored retinal images. Micro aneurysms are small blood clots caused by local distension of capillary walls and appear as small red dots. Blood vessels walls are thin and rupture easily to cause hemorrhages. Hard exudates are yellow lipid deposits which appear as bright yellow lesions. The bright circular region from where the blood vessels originate is called the optic disk. The spatial distribution of exudates and micro aneurysms and hemorrhages, especially in relation to the fovea can be used to determine the severity of diabetic retinopathy.

V. Experimental Results

We used a dataset of 110 images for evaluating the algorithm. The images were obtained from Dr Manoj Saswade one of the renowned Diabetic Eye Specialist and those patients images are used whose treatment is going on. Fundus Images quality and illumination is so important to identify defects present in patients iris due to Diabetes. The images in the dataset were classified by ophthalmologists based on the lesion type (exudates/MAHMs) into those with the lesion and those without it. An image having no lesions is considered normal whereas one that has lesions like exudates, micro aneurysms and hemorrhages is considered abnormal. Among the 110 images obtained from eye hospitals, 78 are diagnosed as Mild Non Proliferative Diabetic Retinopathy and 32 are observe Diabetic Retinopathy patient.

All the images were taken by using fundal equipment i.e. Topcon NW series fundus image camera. Out off 110 images 45 images were identified by ophthalmologists as having exudates and did not have any exudates. A total of 48 images were identified as containing micro aneurysms/ hemorrhages while 21 were free from this lesion type. The entire algorithm was run on the database and results for optic disk localization, exudates detection and MAHMs detection were obtained. The matlab code takes 4 seconds per image on an average to run on a 2 GHz machine with 4GB RAM. The pixel location obtained prior to placing the circular mask is considered for evaluation purposes. If the pixel location indicated by the optic disk algorithm falls within the boundaries of the optic disk, then it is considered a correct detection and vice-versa.

Diabetic retinopathy (DR) is a vascular disorder affecting the microvasculature of the retina. It is estimated that diabetes mellitus affects 4% of the world's population almost half of whom have some degree of DR at any given DR occurs. As we mentioned earlier in Literature survey that there is need of such a automated system to get reed out of it. There are huge number of DR patients who are suffering, and facing vision loss and other micro vascular problems. So in proposed system we obtain sensitivity and specificity results algorithm at both the image and pixel levels.

The main objective of this system is to define severity of the disease using fundus image. In following figure 7 shown

that the given fundus image of diabetic patient has mild non proliferative retinopathy.

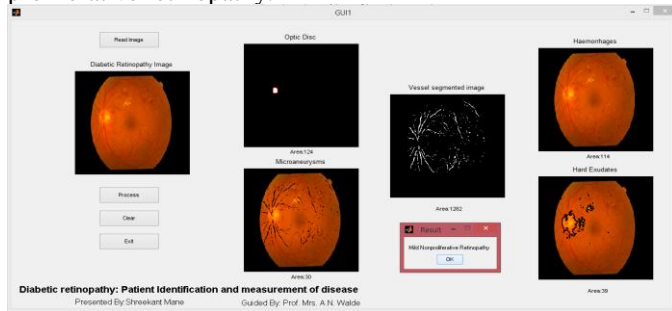


Fig. 7 Mild Non Proliferative Diabetic Retinopathy

This system attenuates image variation by normalizing the original retinal image against a reference model. Variations typically arise within the same image intra image variability as well as between images inter image variability and to enable efficient image analysis which is necessary to compensate for this variability.

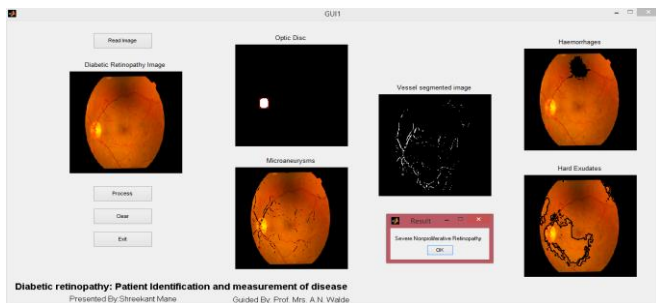


Fig. 8 Severe Non proliferative Diabetic Retinopathy

Diabetic Retinopathy patient identification system is robust to define severity of the Disease. In figure 8 shown that the given patient has severe Diabetic Retinopathy because of exudates and hemorrhages contains available. This Color features can be calculate using morphological classifier, which is used to classify pixel into lesion or non lesion classes. Gold slandered test is used in medical image processing. Given system has accuracy in identifying all the retinal images 100%. The system accuracy to define severity as per fundus image contain is 86.36%. Diabetic Retinopathy and normal retina was classified automatically using image processing and multilayer artificial neural network where input layer outcomes and hidden layer weights which is adjusted accordingly and defines the severity of the disease as per the features of DR fundus image. The system yielded a sensitivity of 87.09% and a specificity of 82.35%. Automated diagnosis based on three lesions exudates, hemorrhages and micro aneurysms.

ACKNOWLEDGMENT

The authors would like to thank the referees for their detailed and useful suggestions and giving opportunity to present our proposed work, which has helped to greatly to improve.

REFERENCES

[1] Thomas Walter, Jean Claude Klein, Pascale Massin, and Ali Erginay, "A Contribution of Image Processing to the Diagnosis of Diabetic

Retinopathy Detection of Exudates in Color Fundus Images of the Human Retina", IEEE Transactions on Medical Imaging, Vol. 21, No. 10, pp 1236-1243, October 2002

[2] Joes Staal, Michael D. Abramoff, Meindert Niemeijer, Max A. Viergever, and Bram van Ginneken, "Ridge-Based Vessel Segmentation in Color Images of the Retina", IEEE Transactions on Medical Imaging, Vol. 23, No. 4, pp 501-508, April 2004.
Alan D. Fleming, Sam Philip, Keith A. Goatman, John A. Olson, and Peter F. Sharp, "Automated Microaneurysm Detection Using Local Contrast Normalization and Local Vessel Detection", IEEE Transactions on Medical Imaging, Vol. 25, No. 9, pp 1223-1232, September 2006s.

[3] Gary G. Yen, and Wen Fung Leong, "A Sorting System for Hierarchical Grading of Diabetic Fundus Images: A Preliminary Study", IEEE Transactions on Information Technology in Biomedicine, Vol. 12, No. 1, pp 118-130, January 2008.

[4] Arturo Aquino, Manuel Emilio Gegundez-Arias, and Diego Marin, "Detecting the Optic Disc Boundary in Digital Fundus Images Using Morphological, Edge Detection, and Feature Extraction Techniques", IEEE Transactions on Medical Imaging, Vol. 29, No. 11, pp 1860-1869, November 2010.

[5] Keerthi Ram, Gopal Datt Joshi, and Jayanthi Sivaswamy, "A Successive Clutter-Rejection-Based Approach for Early Detection of Diabetic Retinopathy", IEEE Transactions on Biomedical Engineering, Vol. 58, No. 3, pp 664-673, March 2011.

[6] Ramon Pires, Herbert F. Jelinek, Jacques Wainer, Siome Goldenstein, Eduardo Valle, and Anderson Rocha, "Assessing the Need for Referral in Automatic Diabetic Retinopathy Detection", IEEE Transactions on Biomedical Engineering, Vol. 60, No. 12, pp 3391-3397, December 2013.