

EFFECT OF ZINC AND VITAMIN E ON SOME BIOCHEMICAL AND HISTOLOGICAL CHANGES IN THE GASTRIC MUCOSA OF ETHANOL INDUCED ULCEROGENIC WISTAR RATS

Oladunni O. Otanwa¹, Ismaila A. Umar², Olumuyiwa A. Owolabi³

Department of Biochemistry, Faculty of Science, Ahmadu Bello University, Zaria, Kaduna State, Nigeria

¹labake10@yahoo.com

Abstract— The experiments were performed to determine the effect of administering zinc and vitamin E on the gastric mucosa of ethanol-induced ulcerogenic rats. Forty-two adult rats comprising both sexes served as subjects. They were shared into seven groups I - VII of six rats per group. Drugs were administered orally for seven days. Group I - received distilled water only; Group II - ethanol 5ml/kg; Group III - 100 mg/kg cimetidine + 5 ml/kg ethanol; Group IV - 100 mg/kg vitamin E + 5 ml/kg ethanol; Group V - 50 mg/kg zinc gluconate + 5 ml/kg ethanol; Group VI - 100 mg/kg vitamin E + 50 mg/kg zinc gluconate + 5 ml/kg ethanol; Group VII - 100 mg/kg vitamin E + 50 mg/kg zinc gluconate only. At the end of the experiment, the animals were sacrificed and their stomachs collected and examined for lesions, the gastric mucus was estimated and their histopathology section analyzed. The results showed that ethanol administration caused significant ($P < 0.05$) increase in the ulcer index as indicated in group II ($11.9 \pm 2.83\%$) while, the groups administered with vitamin E alone ($6.0 \pm 0.63\%$) and zinc alone ($1.2 \pm 0.20\%$) showed significant ($P < 0.05$) decrease in the ulcer index and the co-administration of the zinc and vitamin E further decreased the value ($0.9 \pm 0.11\%$) although there was no significant difference between the values for zinc alone and the co-administration of zinc and vitamin E. Gastric mucus results showed that there was significant ($P < 0.05$) difference between groups treated with zinc alone (7.5 ± 0.10 mg dye absorbed/g tissue) and vitamin E (2.7 ± 0.40 mg dye absorbed/g tissue) alone compared to the negative control group (4.0 ± 0.20 mg dye absorbed/g tissue). Thus, it was concluded that zinc and vitamin E ameliorated ethanol induced lesions and the gastric mucus as observed by the percentage index calculated (Zinc- 89.2% and vitamin E- 49.58%) in the ulcerogenic rats.

Index Terms: Ethanol, zinc, vitamin E, ulcer index, gastric mucus, gastric mucosa.

I. INTRODUCTION

Peptic ulcers are open sores, which develop on the inner mucosal lining of the digestive tract; it is the most prevalent chronic gastro-intestinal disorder in nature. It occurs mainly on

the initial portion of the small intestine, oesophagus and stomach [1, 2]. Peptic ulcers occur with loss of mucus membrane of any part of the gastro-intestinal tract, exposed to pepsin or acidic contents of the gastric juice [3]. The pathophysiology of ulcer usually involves an imbalance between the aggressive and defensive mucosal factors[4]. The aggressive factors include hydrochloric acid, pepsin and *Helicobacter pylori*, which are injurious; while, the defensive mucosal factors include: mucin, prostaglandin, bicarbonate, nitric oxide and growth factors[4, 5, 6]. Gastric mucus consists of viscous, elastic adherent and transparent gel formed by water and glycoprotein. The protective effects of the mucous barrier depend not only on the gel structure, but also on the amount or thickness of the layer covering the mucosal surface [7]. The gastric mucosa has the ability to resist injury caused by endogenous secretions (such as acid, pepsin and bile) and by ingested irritants such as alcohol, aspirin and non-steroidal anti-inflammatory drugs (NSAIDs); this can be attributed to factors involved in mucosal defence [8]. In healthy individuals, the digestive tract is coated with a mucous membrane that protects the underlying tissue against the highly corrosive digestive, hydrochloric acid. If the amount of the acid increases or the pH reduces significantly, the acid damages the tissue; thus, leading to ulceration [9]. Vitamin E is a major lipid-soluble antioxidant present in all cellular membranes, which protects against lipid peroxidation [10, 11]. It functions as a chain-breaking antioxidant by preventing chain initiation and propagation of free-radical reactions and lipid peroxidation in cell membranes [12]. Thus, Vitamin E can be said to play an important role in cell survival by scavenging free radicals and other reactive substances [13]. The vitamin has been suggested as a universal stabilizer of biological membranes in normal oxygen metabolism and peroxidation as well as in metabolic disorders, it therefore plays a vital role in the stabilisation of cell membranes and maintenance of their permeability [10, 14]. Vitamin E supplementation significantly lowers lipid peroxidation through increased glutathione levels [15]. It is involved in nucleic acid and protein metabolism, functions of

the mitochondria and regulation of hormone production. It is required for normal functions of the immune system and control of aggregation of platelets [16]. Gastro-intestinal mucosal cells rely on both luminal and bloodstream sources for their nutrition. Some nutrients and essential micronutrients are proposed to promote gastro-intestinal mucosal integrity include; amino acids (glutamine and arginine), vitamin A and zinc [17]. Zinc is a micronutrient, an essential trace element for humans, animals and plants [18, 19]. It is involved in numerous aspects of cellular metabolism and is required for the catalytic activity of several enzymes [20]. Zinc is not an antioxidant, but may limit oxidant-induced damages in several ways, some of which include; protection against vitamin E depletion, stabilization of membrane structure and restriction of endogenous free radical production [18, 21]. Alcohol breakdown in the liver results in the formation of molecules, whose further metabolism in the cells leads to increased generation of reactive oxygen species (ROS) [22]. Alcohol stimulates the activity of enzymes called cytochrome P_{450s}, which contribute to free-radical generation and also reduces the levels of agents, capable of eliminating ROS such as selenium, zinc and vitamin E [23]. Ethanol being a necrotizing agent damages the superficial epithelial layers and inhibits the release of mucosal prostaglandins [6, 24]. The mechanism of ethanol-induced gastric lesions is varied, including the depletion of gastric mucus content, damaged mucosal blood flow and mucosal cell injury [25]. The aim of the present study was to determine the extent which zinc and vitamin E could protect the gastric mucosa of ethanol-induced ulcerogenic rats from damage. The degree of damage was observed by the ulcer-index and the histopathological studies conducted.

II. MATERIALS AND METHODS

Experimental Animals and Management

Fourty-two adult male and female Wistar rats weighing between 150-200 g served as subjects and were obtained from Department of Pharmacology, Faculty of Pharmaceutical Sciences, Ahmadu Bello University, Zaria. They were housed in well-ventilated cages and maintained under standardized laboratory conditions at temperature ranging between 24-26°C and a 12-hr light/ 12-hr dark cycle. The rats were given access to commercial laboratory diet and water *ad libitum*.

Animal Grouping

The rats were assigned equally into seven groups, consisting of six rats each (n = 6). They were administered with drugs orally for seven days as follows: Group I – (Control) received distilled water only; Group II – received 5 ml of absolute ethanol only [26]; Group III – received cimetidine (Surelife Pharmaceutical Company, Nigeria) at 100 mg/kg body weight and ethanol [27]; Group IV – received vitamin E (Archy's International Health Supplies and Services, Baltimore, Maryland, USA) (100 mg/kg) [28] and ethanol (5 ml); Group V – received zinc gluconate (Good 'N Natural®, Bohemia, New York 11716, USA) (50 mg/kg) [29] and ethanol (5 ml); Group VI - received vitamin E (100 mg/kg) and zinc gluconate + ethanol (5 ml). [28, 29]; Group VII - received vitamin E (100 mg/kg) and zinc gluconate only [28, 29]. After the treatment, ulcer was induced with absolute ethanol. One

hour afterwards, the animals were sacrificed under chloroform-induced anaesthesia [30].

Gastric Ulcer-induction by Absolute Ethanol

The rats were fasted for 48 hours before the commencement of the experiment as described by Abdulla *et al.* (2010) [31], but they were allowed free access to drinking water up till 2 hours before being sacrificed. Gastric ulcer was induced by orogastric intubation of absolute ethanol (5 ml/kg body weight) according to the method described by Mahmood *et al.* (2010) [32].

III. DETERMINATION OF GASTRIC ULCER PARAMETERS

A. Determination of Ulcer Index

The gastric lesions were evaluated according to the method described by Nwafor *et al.* (1996) [33], where the ulcer lesions observed as elongated black-red lines parallel to the long axis of the stomach were scored according to the severity of the ulcer as follows;

0 = No ulcer

1 = Haemorrhagic and slightly dispersed ulcers less than 2 mm in length

2 = One ulcer, haemorrhagic and up to 5 mm length

3 = More than one ulcer, each up to 5 mm in length

4 = One ulcer above 5 mm in length

5 = More than one ulcer above 5mm in length

The ulcer index (UI), defined as the severity of damage caused by an ulcer-inducing agent, was then calculated using the following formula:

$$UI = UA/TA \times 100$$

Where UA = Ulcer area of stomach mucosa

TA = Total area of stomach mucosa

B. Determination of Preventive Index

The preventive index (PI), which is the degree of protection offered by a treatment against ulcer-causing agent, was calculated using the formula as described by Hano *et al.*, 1976 [34]:

$$PI = \left[\frac{\text{MUI control} - \text{MUI treated}}{\text{MUI control}} \right] \times 100$$

Where MUI = mean ulcer index

C. Determination of Gastric Mucus

The mucus of the gastric wall was determined by the method of Corne *et al.*, (1974) [35] as modified by Al-Mofleh *et al.*, (2006 [36]). Briefly, the glandular segments of the stomach was weighed and transferred into a solution of 0.1% w/v Alcian blue in 0.16 M sucrose solution, buffered with 0.05 M Sodium acetate at pH 5. The tissue was stained for two hours after which the excess dye was rinsed twice successively with 0.25 M sucrose for 15 min, and subsequently for 45 min. The dye complexed with the gastric mucus was then extracted with 10 ml of 0.5 M MgCl₂, and was shaken intermittently for one minute at 30-min intervals for 2h. The extract (4 ml) was then shaken with equal volume of diethylether. The emulsion obtained was then centrifuged at 3600 rpm for 10 minutes and

the absorbance of the aqueous layer was recorded at 580 nm. The quality of the dye extracted per gram of wet glandular tissue was then calculated.

D. Histological Evaluation of Gastric Lesions

Histological evaluation was carried out by method of Culling (1974) [37]. Specimens of the gastric walls of each rat were fixed in 10% buffered-formalin and processed in a paraffin tissue processing machine. Sections of the stomach were made at a thickness of 5 μ m and stained with haematoxylin and eosin for histological evaluation and viewed at a magnification of x 100 [38].

E. Statistical Analysis

Data obtained were expressed as mean \pm standard error of the mean (Mean \pm SEM). The obtained data were subjected to one-way analysis of variance (ANOVA), followed by Duncan's multiple range test using statistical package for social sciences (SPSS) version 17.0. Values of $P < 0.05$ were considered significant.

IV. RESULTS

The ulcer index obtained following the induction of ulcer by ethanol in the negative control group was $11.9 \pm 2.83\%$, and the index was significantly ($P < 0.05$) reduced to $6.0 \pm 0.63\%$ and $0.9 \pm 0.11\%$ in rats administered with zinc and ethanol alone and zinc, vitamin E and ethanol combined, respectively. The index was lower in zinc-treated ulcerogenic rats, when compared respectively to the index obtained in ethanol-induced ulcerogenic rats. In cimetidine-treated rats, the index was significantly ($P < 0.05$) higher than that recorded in zinc-treated ulcerogenic rats or zinc, vitamin E and ethanol-treated rats. Vitamin E showed the highest ulcer index in ulcerogenic rats when compared respectively to either cimetidine group or any other group.

The result of the gastric mucus of the stomach of the rats expressed in terms of mg dye absorbed per g of tissue is presented in Table 1 below. Again, zinc-treated rats had a higher value of gastric mucus (7.5 ± 0.10 mg dye absorbed/g of tissue) than in ulcerogenic rats, treated with vitamin E alone (2.7 ± 0.40 mg dye absorbed/g of tissue) or the combination of zinc and vitamin E (6.9 ± 0.50 mg dye/g of tissue) or cimetidine (3.6 ± 0.10 mg dye /g of tissue). The gastric mucus value obtained in ulcerogenic rats treated with a combination of zinc plus vitamin E (6.9 ± 0.50 mg dye/g of tissue) did not differ ($P > 0.05$), when compared with that recorded in ulcerogenic rats treated with zinc alone (7.5 ± 0.10 mg dye/g of tissue). Treatment of the ulcerogenic rats with vitamin E alone gave the lowest gastric mucus value of 2.7 ± 0.40 , and this value was significantly ($P < 0.05$) the lowest, when compared to that recorded in any other group. The highest gastric mucus value was recorded in zinc plus vitamin E-treated normal group; with 12.3 ± 1.30 mg dye/g of tissue. This value was significantly ($P < 0.05$) higher than any other value of gastric mucus obtained in the groups, including the normal control group which had gastric mucus value of 5.5 ± 0.90 mg dye/g of tissue.

The preventive index, expressed as a percentage and a measure of the efficacy of the supplements used in comparison with the mean ulcer index of the negative control (ethanol), is presented in Table 1. The highest preventive ratio of 92.44% was recorded in rats administered with both zinc and vitamin E, and this value was closely followed by 89.92% recorded in ulcerogenic rats treated with zinc. The least preventive ratio of 49.58% was obtained in ulcerogenic rats administered with vitamin E.

Histological evaluation of the ethanol-induced gastric lesions in the ulcer control group (without treatment) showed gross extensive damages to the gastric mucosa. The damages included disruption of the epithelium, necrosis of the mucosa, with leucocyte infiltration of the mucosal layer (Plate B). Rats treated with zinc, vitamin E and zinc plus vitamin E had comparatively better protection of the gastric mucosa as evidenced by the reduction in the ulcerated area, reduced or absence of necrosis and leucocytic infiltration (Plate C-F). Plates A and G show normal gastric mucosa, and with treatment, (Zinc + Vitamin E) respectively.

V. DISCUSSION

The result of the present study is in agreement with the established finding that absolute ethanol is commonly used for induction of ulcer and it leads to intense gastric mucosal damage [39, 40, 41, 42]. Although the proximate mechanism underlying the induction of gastric mucosal damage was not elucidated in the present study, previous studies suggest that the ethanol-induced injury to the gastro-intestinal mucosa starts with microvascular injury, which includes disruption of the vascular endothelium and resulting in increased vascular permeability, oedema formation and epithelial lifting [43]. The result of the present study demonstrated that zinc alone was more protective against gastric mucosa damage, induced by ethanol than vitamin E alone. The protection induced by vitamin E was the least as evidenced by a higher ulcer index, compared to that of zinc. This result is in agreement with the finding of Ismail *et al.* (1999) [44], who suggested that vitamin E accelerates healing of gastric lesions, but may not prevent the formation of ethanol-induced lesions. The findings of the present study showed that zinc alone was more protective than both vitamin E alone and even the conventional anti-histaminic drug, cimetidine, an H₂-receptor antagonist (H₂-blocker). The least ulcer index of $0.9 \pm 0.11\%$, obtained in the group treated with a combination of the two antioxidants, vitamin E and zinc, may be as a result of the ability of both zinc and vitamin E to stabilize the membrane [45]. Thus, the combination increased the potency of the action of the two antioxidants, resulting in synergistic effects. Both the normal and, in particular, the antioxidant control showed that neither the distilled water nor any of the two antioxidants administered exerted any deleterious effect on the gastric mucosa. This observation may be responsible for the lack of ulcer index (0%) obtained in both control groups.

Although the proximate mechanism of action of zinc and vitamin E in reducing the damages caused by ethanol on the gastric mucosa which resulted in ulcer was not investigated in the present study, zinc and vitamin E have been established as potent antioxidant agents, involved in the protection of

cytomembranes from injury [29, 46, 47]. Furthermore, zinc, which is an essential trace element, is a component of some antioxidants in the body, including zinc-superoxide dismutase [46]. Zinc-superoxide dismutase is involved in the dismutation of superoxide radical, subsequently converted to water by the glutathione peroxidase [45, 48, 49]. The finding of the present study demonstrated that ROS are, apparently, involved, at least in part, in the mechanism underlying the ulcerogenesis [7] since administration of antioxidants ameliorated the ulcer index in rats, especially a combination of vitamin E and zinc. This finding is of practical application. Individuals with ulcer may, therefore, benefit from the administration of zinc and/or vitamin E and, especially, a combination of the two antioxidants. By implication, a rational supplementation with vitamin E and diets rich in zinc may be protective against ulcerogenesis. Such supplements include oysters, red meat, organ meats. Others are liver, beans, nuts, seafood such as crab and lobster; whole grains, cereals, almonds, pumpkin seeds, sunflower seeds; and some natural zinc sources, which are: bran, grains and fodder yeast [46, 50, 51]. The supplements and foods may be gastro-protective and, thus ameliorate the adverse effects of ulcer in individuals consuming large quantities of alcohol or ulcer-induced by other sources. The result of the present study demonstrated that agents acting on H₂-receptors may be partly responsible for the induction of ulcer in individuals with the disease, and it agreed with the finding of Iyyam Pillai *et al.* (2010) [7] that ROS also play a significant role in ulcerogenesis.

The result of the gastric mucus value and preventive ratio showed that zinc alone was more protective than vitamin E, and that a combination of zinc and vitamin E all the more gave a better protection. The finding is in agreement with the results of Banos and Bulbena (1989) [52] and Bandyopadhyay and Bandyopadhyay (1997) [53], who showed that zinc reduces acid secretion and increases mucus secretion. The result obtained in the present study has further demonstrated that zinc and/or vitamin E protect gastric cells from injuries, particularly the combination of the two antioxidants. The present result, which showed that the least preventive index and gastric mucus value were obtained in rats administered with vitamin E, agree with the finding of Ismail *et al.* (1999) [44], that palm vitamin E alleviated ethanol-induced gastric lesions. Therefore, zinc alone or its combination with vitamin E, and not vitamin E alone, may be more therapeutic in action than vitamin E alone or even cimetidine, with gastric mucus value of 3.6 ± 0.10 mg dye/g tissue and preventive ratio of 73.11%. The result of the present study has shown that either zinc alone or its combination with vitamin E has a more potent therapeutic effect in gastric ulcer, induced by ethanol than even cimetidine, the conventional anti-histaminic agent (positive control). It is worth noting that the antioxidants which are less toxic, readily available than cimetidine gave a better therapeutic effect in ulcerogenic rats than the conventional anti-histaminic agent, cimetidine. The present study has, therefore, shown that, not only that the antioxidants are more potent, but also that their combination exerted a synergistic effect.

The induction of gastric ulcer by ethanol in the present study agrees with the previous findings that the alcohol produces necrotic lesions in the gastric mucosa by its direct

toxic effect, by reducing the secretion of bicarbonates and production of mucus [41, 54]. This observation was supported by the decrease in the damage, obtained following treatment with zinc and vitamin E. Thus, oral administration of absolute ethanol is noxious to the stomach as it affects the gastric mucosa topically by disrupting its barrier and provoking pronounced microvascular changes within few minutes of administration [55]. Furthermore, the result of the present study agreed with the findings of Jelski *et al.* [56], which showed that ethanol produces linear haemorrhagic lesions, extensive sub-mucosal oedema, mucosal friability, inflammatory cell infiltration, and epithelial cell loss in the stomach. Thus, the supplements exerted cytoprotective effects on the gastric mucosa.

VI. CONCLUSION

In conclusion, vitamin E and zinc, in the form of nutritional supplements, exerted protective effect against ethanol-induced ulcer. The combination of zinc and vitamin E gave the highest protective ratio, indicating a higher potential as a means of protection against gastric ulcer

REFERENCES

- [1] Valle, J. O. (2008). Peptic ulcer disease and related disorders. In: Fauci, A.S., Braunwald, E., Kasper, D.L., Hauser, S.L., Longo, D.L., Jameson, J.L., and Loscalzo, J., (Editors). *Harrison's Principles of Internal Medicine*, , McGraw-Hill, New York, pp.1855-1872.
- [2] Dufton, J. (2012). The pathophysiology and pharmaceutical treatment of gastric ulcers. *Council for Pharmacy Education*, 12: 747-771.
- [3] Umana, U. E., Timbuk, J. A., Musa, S. A., Ikyembe, D. T., Abdurrashid, S. and Hamman, W. O. (2012). Ulceroprotective effect of methanol extract of *Psidium guajava* leaves on ethanol-induced gastric ulcer in adult wistar rats. *Asian Journal of Medical Sciences*, 4(2): 75-78.
- [4] Wallace, J. L. and Sharkey, K. A. (2011). Pharmacotherapy of gastric acidity, peptic ulcers and gastroesophageal reflux disease. In: Brunton, L.L., Chabier, B.A., and Knollmann, B.C., (Eds.). *The Pharmaceutical Basis of Therapeutics*, McGraw-Hill, New York, Pp.1309-1322.
- [6] Lahiri, S. and Palit, G. (2012). And overview of the current methodologies used for evaluation of gastric and duodenal anti-ulcer agents. *Pharmacologia*, 3(8): 249-257.
- [7] Iyyam Pillai, S., Kandaswamy, M. and Subramanian, S. (2010). Antiulcerogenic and ulcer healing effects of indian propolis in experimental rat ulcer models. *Journal of Api Medical Science*, 2(1): 21-28.
- [8] Wallace, J. L. (2001). Non steroidal anti-inflammatory drugs and the gastrointestinal tract. Mechanisms of protection and healing: current knowledge and future research. *The American Journal of Medicine*, 110:19S-23S.
- [9] Luiz-Ferreira, A., Cola, M., Barbastefano, V., Hiruma-Lima, C. A., Santos, L. C., Vilegas, W. and Brito, A. R. M. (2012). Antiulcerogenic activity of aqueous fraction of

Anacardium humile St. Hil (Anacardiaceae), *Journal of Medicinal Plants Research*, 6(40): 5337-5343.

[10] Ambali, S. F., Ayo, J. O., Ojo, S. A. and Esievo, K. A. N. (2010). Vitamin E protects Wistar rats from chlorpyrifos-induced increase in erythrocyte osmotic fragility. *Food and Chemical Toxicology*, 48: 3477-3480.

[11] Ibitoroko, G. M., Adebayo, A. O. and Wachukwu, C. K. (2011). Effects of vitamin E and C on haematological parameters in albino rats treated with gasoline, *Global Veterinaria*, 7(4): 347-352.

[12] Kamal-Eldin, A. and Appelqvist, L. A. (1996). The chemistry and antioxidant properties of tocopherols and tocotrienols. *Lipids*, 31: 671-701.

[13] Halliwell, B. (1994). Free radicals and antioxidants: a personal view. *Nutritional Reviews*, 52: 253-265.

[14] Navarro, F., Arroyo, A., Martin, S. F., Bello, R. I., De Cabo, R., Burgess, Jr., Navas, P. and Villalba, J. M. (1999). Protective role of ubiquinone in vitamin E and selenium-deficient plasma membranes. *Biofactors*, 9: 163-170.

[15] Sushil, K. J., Robert, M. V. and Tiney, S. (2000). Vitamin E supplementation restores glutathione and malondialdehyde to normal concentrations in erythrocytes of type I diabetic children. *Journal of Diabetic Children, Diabetic Care*, 23(9): 1389-1394.

[16] Yarube, I. U. (2011). Nitrate-induced oxidative stress and the effects of dietary antioxidant vitamins C, E and A: insights from experimental and clinical studies. *Bayero Journal of Pure and Applied Sciences*, 4(2): 69-79.

[17] Duggan, C., Gannon, J. and Walker, A.W. (2002). Protective nutrients and functional foods for the gastrointestinal tract. *The American Journal of Clinical Nutrition*. 75: 5789-5808.

[18] Das, M. and Das, R. (2012). Need of education and awareness towards zinc supplementation: A review. *International Journal of Nutrition and Metabolism*, 4(3): 45-50.

[19] Çelik, E. Ş., Kaya, H., Yilmaz, S., Akbulut, M. and Tulgar, A. (2013). Effects of zinc exposure on the accumulation, haematology and immunology of Mozambique tilapia, *Oreochromis mossambicus*, *African Journal of Biotechnology*, 12(7): 744-753.

[20] Murase, H., Sakai, S., Kusano, K., Hobo, S. and Nambo, Y. (2012). Serum zinc levels and their relationship with diseases in racehorses, *The Journal of Veterinary Medical Science*, 75(1): 37-41.

[21] DiSilvestro, R. A. (2000). Zinc in relation to diabetes and oxidative disease. *Journal of Nutrition*, 130: 1509s-1511s.

[22] Toykuni, S. (1999). Reactive Oxygen Species induced molecular damage and its implication in Pathology, *Pathology International*, 49: 19-102.

[23] Ligha, A. E. and Fawehinmi, H. B. (2009). Protection by liquorice in alcohol induced gastric mucosa damage. *Pakistan Journal of Nutrition*. 8(10): 1532-1536.

[24] De-Faria, F. M., Almeida, A. C., Luiz-Ferreira, A., Dunder, R. J., Takayama, C., da-Silva, M. S., da Silva, M. A., Vilegas, W., Rozza, A. L., Pellizzon, C. H., Toma, W. and Souza-Brito, A. R. (2012). Mechanisms of action underlying the gastric antiulcer activity of the *Rhizopora mangle* L., *Journal of Ethnopharmacology*, 139(1): 234-243.

[25] Kumar, S., Ramica, S., Robin, S. and Amandeep, K. (2012). Peptic ulcer: a review on etiology and pathogenesis. *International Research Journal of Pharmacy*, 3(6): 34-38.

[26] Arafa, H. M. M. and Sayed-Ahmed, M. M. (2003). Protective role of carnitine esters against alcohol-induced gastric lesions in rats. *Pharmacological Research*, 48: 285-290.

[27] Satoh, H., Guth, P. H. and Grossman, M. I. (1983). Role of bacteria in gastric ulceration produced by indomethacin in the rat: cytoprotective action of antibiotics. *Gastroenterology*, 84: 483-489.

[28] Amazan, D., Rey, A. I., Fernandez, E. and Lopez-Bote, C. J. (2012). Natural vitamin E (D- α -tocopherol) supplementation in drinking water prevents oxidative stress in weaned piglets. *Livestock Science*, 145: 55-62.

[29] Ambali, S. F., Abubakar, A. T., Kawu, M. U., Uchendu, C., Shittu, M. and Salami, S. O. (2011). Biochemical alterations induced by subchronic chlorpyrifos exposure in Wistar rats: ameliorative effect of zinc. *Journal of American Science*, 7(9): 73-81.

[30] Al-Harbi, M. M., Quersh, S. and Rasa, M. (1997). Gastric antiulcer and cyto-protective effect of *Commiphora molmol* in rats. *Journal of Ethnopharmacology*, 55: 141-150.

[31] Abdulla, M. A., Ahmed, K. A. A., Al-Bayaty, F. H. and Masood, Y. (2010). Gastro-protective effect of *Phyllanthus niruri* leaf extract against ethanol-induced gastric mucosal injury in rats. *African Journal of Pharmacy and Pharmacology*, 4(5): 226-230.

[32] Mahmood, A. A., Mariod, A. A., Al-Bayaty, F. and Abdel-Wahab, S. I. (2010). Anti-ulcerogenic activity of *gynura procumbens* leaf extract against experimentally-induced gastric lesions in rats. *Journal of Medicinal Plants Research*, 3: 685-691.

[33] Nwafor, K. D., Effraim, K. D. and Jacks, T. W. (1996). Gastroprotective effects of the aqueous extract of *Khaya senegalensis* bark on indomethacin-induced ulceration in rats. *West African Journal of Pharmacology and Drug Research*, 12: 46-50.

[34] Hano, J., Bogajski, J., Danek, L. and Wantuch, C. (1976). The effect of neuroleptic development of gastric ulcers in rats exposed to restraint cold stress. *Polish Journal of Pharmacology*, 28: 37-47.

[35] Corne, S. J., Morrissey, S. M. and Wood, R. J. (1974). A method for the quantitative estimation of gastric barrier mucus. *Journal of Physiology*, 242: 116P-117P.

[36] Al-Mofleh, L. A., Alhaider, A. A., Mossa, J. S., Al-Sohaibani, M. O., Qureshi, S. and Rafatullah, S. (2006).

Antigastric ulcer studies on 'saffron' *Crocus sativus* L. in rats. *Pakistan Journal of Biological Sciences*, 9(6): 1009-1013.

[37] Culling, C. F. A. (1974). *Handbook of Histopathological and Histochemical Techniques*. Third Edition, Butterworth and Co., London, pp. 126-159.

[38] Ketuly, K. A., Abdulla, M. A., Hadi, H. A., Mariod, A. A. and Abdel-Wahab, S. I. (2011). Anti-ulcer activity of the alpha-bromo analogue of *Beclomethasone dipropionate* against ethanol-induced gastric mucosal injury in rats. *Journal of Medicinal Plants Research*, 5(4): 514-520.

[39] Salawu, O. A., Tijani, A. Y., Obidike, I. C., Rafindadi, H. A. and Emeje, M. (2009). Anti-ulcerogenic properties of methanolic root extract of *Piliostigma reticulatum* (DC) Hoescht (Syn. *Bauhinia reticulata* DC) – Leguminosae in rats. *African Journal of Pharmacy and Pharmacology*, 3(5): 255-258.

[40] Ubaka, M. C., Ukwe, V. C., Okoye, C. T. and Adibe, O. M. (2010). Investigation into the anti-ulcer activity of the aqueous leaf extract of *Aspilia Africana* C.D.Adams, *Asian Journal of Medical Sciences*, 2(2): 40-43.

[41] Al-Radahe, S., Ahmed, A. K., Salama, S., Abdulla, M. A., Amin, Z. A., Al-Jassabi, S. and Hashim, H. (2012). Anti-ulcer activity of *Swietenia mahagoni* leaf extract in ethanol-induced gastric mucosal damage. *Journal of Medicinal Plants Research*, 6(12): 2266-2275.

[42] Hussaini, J., Othman, N. A., Abdulla, M. A., Majid, N. A., Farooq, H. M. and Ismail, S. (2012). Gastroprotective effects of *Dicranopteris linearis* leaf extract against ethanol-induced gastric mucosal injury in rats, *Scientific Research and Essays*, 7(18): 1761-1767.

[43] Szabo, S., Kusstatscher, S., Sakoulas, G., Sandor, Z., Vincze, A. A. and Jadus, M. (1995). Growth factors: New "endogenous drug" for ulcer healing. *Scandinavian Journal of Gastroenterology*, 210: 15-18.

[44] Ismail, N. M., Jaarin, K., Ahmad, A., Marzuki, A., Ng, W. K. and Gapor, M. T. (1999). Palm vitamin E and the healing of ethanol-induced gastric lesions, *Asia Pacific Journal of Clinical Nutrition*, 8(4): 258-262.

[45] Agarwal, A., Khanna, P., Baidya, D. K. and Arora, M. K. (2011). Trace elements in critical illness. *Journal of Endocrinology and Metabolism*, 1(2): 57-63.

[46] Deshpande, J. D., Joshi, M. M. and Giri, P. A. (2013). Zinc: the trace element of major importance in human nutrition

and health. *International Journal of Medical Science and Public Health*, 2(1): 1-6.

[47] Ambali, S. F., Ayo, J. O., Shittu, M., Kawu, M. U. and Salami, S. O. (2012). Ameliorative effect of vitamin E on sensorimotor and cognitive changes induced by chronic chlorpyrifos exposure in Wistar rats, In: Soloneski, S. (Ed.), *Insecticides- Basic and Other Applications*, Intech, Croatia, pp. 207-232.

[48] Powell, S. R. (2000). The antioxidant properties of zinc. *Journal of Nutrition* 130(5): S1447-S1454.

[49] Dröge, W. (2002). Free radicals in the physiological control of cell function. *Physiological Reviews*, 82: 47-95.

[50] Berdainer, C. D., Dwyer, J. T. and Felman, E. B. (2007). *Handbook of Nutrition and Food*, Boca Raton, Florida: CRC Press. pp. 101-120.

[51] Strnadova, P., Svobodova, V., Pavlata, L., Misurova, L. and Dvorak, R. (2011). Effect of inorganic and organic zinc supplementation on coccidial infections in goat kids. *Acta Veterinaria Brno*, 80: 131-137.

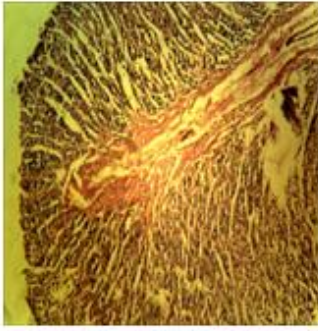
[52] Banos, J. E. and Bulbena, O. (1989). Zinc compounds as therapeutic agents in peptic ulcer. *Methods and Findings in Experimental and Clinical Pharmacology*, 11(1): 117-122.

[53] Bandyopadhyay, B. and Bandyopadhyay, S. K. (1997). Protective effect of zinc gluconate on chemically induced gastric ulcer. *Indian Journal of Medicinal Resources*, 106: 27-32.

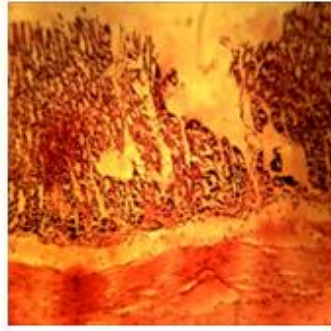
[54] Rujjanawate, C., Kanjanapothi, D., Amornlerdpison and Pojanagaroon, S. (2005). Anti-gastric ulcer effect of *Kaempferia parviflora*. *Journal of Ethnopharmacology*, 102:120-122.

[55] Moleiro, F. C., Andreo, M. A. and Santos, R. D. C. D. (2009). *Mouriri elliptica*: validation of gastroprotective, healing and anti-*helicobacter pylori* effects. *Journal of Ethnopharmacology*, 123(3): 359-368.

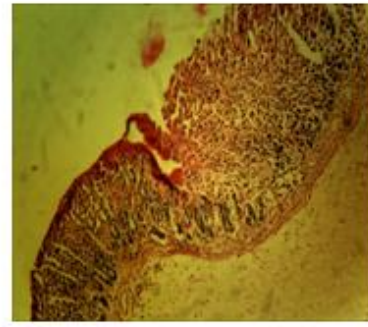
[56] Jelski, W., Kozłowski, M., Laudanski, J., Niklinski, J. and Szmitkowski, M. (2009). The activity of class I, II, III and IV alcohol dehydrogenase (ADH) isoenzymes and aldehyde dehydrogenase (ALDH) in esophageal cancer. *Digestive Diseases and Sciences*, 54(4): 725-730.



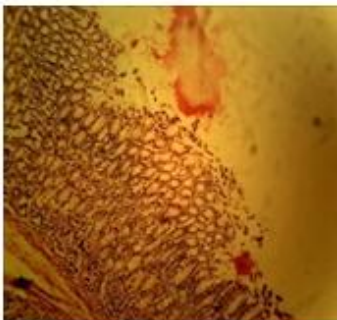
A. Normal Control



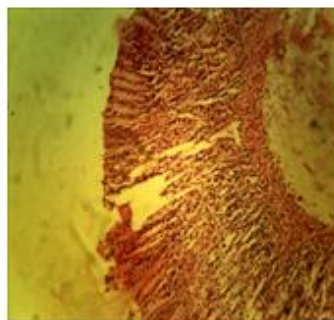
B. Ethanol (5mg/kg)



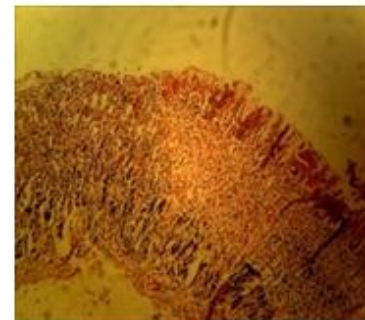
C. Cimetidine(100 mg/kg) + Ethanol (5mg/kg)



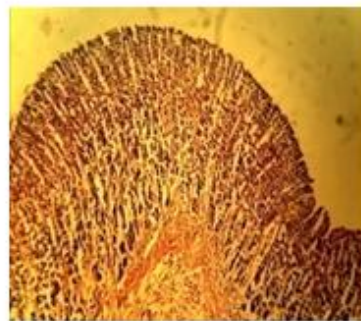
D. Vitamin E (100mg/kg) + Ethanol (5mg/kg)



E. Zinc (50mg/kg) + Ethanol (5mg/kg)



F. Zinc (50mg/kg) + Vitamin E (100mg/kg) + Ethanol (5mg/kg)



G. Zinc (50mg/kg) + Vitamin E (100mg/kg)

A) Photomicrograph of the normal gastric mucosa and submucosa of the rats given distilled water only; **B)** Photomicrograph showing extensive damage to the apical mucosa, characterized by severe damage to the epithelium with marked erosion, necrosis of the mucosal cells and leucocyte infiltration of the mucosa; **C)** photomicrograph showing less severe damage to the gastric mucosa, with lesser degree of erosion and destruction of the surface mucosal cells and leucocyte infiltration; **D)** Photomicrograph showing mild

damage to the gastric mucosa of the rats with infiltration of cells and slight necrosis; **E)** Photomicrograph showing mild erosion of the gastric mucosa with necrosis of cells ; **F)** Photomicrograph showing mild damage to the surface mucosal cells with infiltration of cells with leucocytes; **G)** Photomicrograph showing normal mucosal layer without damage; (H and E stain, x 100)

Table 4.1: Effect of Zinc, Vitamin E and their Combination on Gastric Ulcer Index and Gastric Mucus of Ethanol induced Ulcerogenic Rats.

	Groups						
	I	II	III	IV	V	VI	VII
Ulcer Index (%)	0.00 ± 0.00 ^a	11.9 ± 2.83 ^c	3.2 ± 0.29 ^{ab}	6.0 ± 0.63 ^b	1.2 ± 0.20 ^a	0.9 ± 0.11 ^a	0.00 ± 0.00 ^a
Gastric Mucus (mg dye absorbed/g tissue)	5.5 ± 0.90 ^{bc}	4.0 ± 0.20 ^{ab}	3.6 ± 0.10 ^{ab}	2.7 ± 0.40 ^a	7.5 ± 0.10 ^c	6.9 ± 0.50 ^c	12.3 ± 1.30 ^d
Preventive Index (%)	-	0	73.11	49.58	89.92	92.44	-

Values are means ± SEM of Six (6) determinations

Values with different superscript along the row differ significantly (P < 0.05)

Group I: Normal Control Rats, Group II : Ethanol Induced Rats, Group III: Ethanol Induced Rats Pretreated with Cimetidine (100 mg/kg), Group IV: Ethanol Induced Rats Pretreated with Vitamin E (100 mg/kg), Group V: Ethanol Induced Rats Pretreated with Zn (50 mg/kg), Group VI: Ethanol Induced Rats Pretreated with a Combination of Zinc(50 mg/kg) and Vitamin E (100 mg/kg), Group VII: Normal Rats pretreated with a combination of Zn(50 mg/kg) and Vitamin E (100 mg/kg).